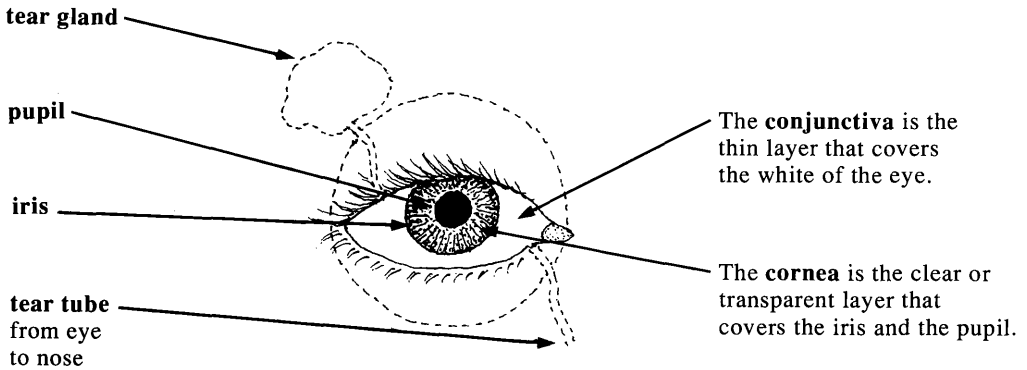

THE EYES

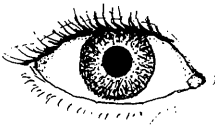
16



DANGER SIGNS


The eyes are delicate and need good care. Get medical help fast when any of the following danger signs occurs:

1. Any injury that cuts or ruptures (goes through) the eyeball.
2. Painful, grayish spot on the cornea, with redness around the cornea (corneal ulcer).
3. Great pain inside the eye (possibly iritis or glaucoma).
4. A big difference in the size of the pupils when there is pain in the eye or the head.



A big difference in the size of the pupils may come from brain damage, stroke, injury to the eye, glaucoma, or iritis. (A small difference is normal in some people.)

5. Blood behind the cornea inside the eyeball (see p. 225).
6. If vision begins to fail in one or both eyes.
7. Any eye infection or inflammation that does not get better after 5 or 6 days of treatment with an antibiotic eye ointment.



INJURIES TO THE EYE

All injuries to the eyeball must be considered dangerous, for they may cause blindness.

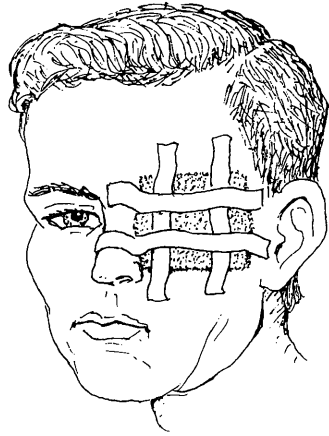
Even small cuts on the **cornea** (the transparent layer covering the pupil and iris) may get infected and harm the vision if not cared for correctly.

If a wound to the eyeball is so deep that it reaches the black layer beneath the outer white layer, this is especially dangerous.

If a blunt injury (as with a fist) causes the eyeball to fill with blood, the eye is in danger (see p. 225). Danger is especially great if pain suddenly gets much worse after a few days, for this is probably acute glaucoma (p. 222).

Treatment:

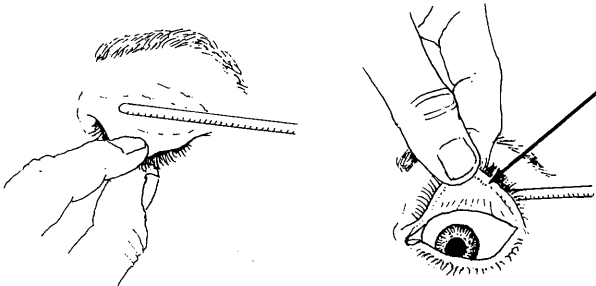
- ◆ If the person still sees well with the injured eye, put an antibiotic eye ointment (p. 378) in the eye and cover it with a soft, thick bandage. If the eye is not better in a day or two, get medical help.
- ◆ If the person cannot see well with the injured eye, if the wound is deep, or if there is blood inside the eye behind the cornea (p. 225), cover the eye with a clean bandage and go for medical help at once. **Do not press on the eye.**
- ◆ **Do not** try to remove thorns or splinters that are tightly stuck in the eyeball. Get medical help.



HOW TO REMOVE A SPECK OF DIRT FROM THE EYE

Have the person close her eyes and look to the left, the right, up and down. Then, while you hold her eye open, have her look up and then down. This will make the eye produce more tears and the dirt often comes out by itself.

Or you can try to remove the bit of dirt or sand by flooding the eye with clean water (p. 219) or by using the corner of a clean cloth or some moist cotton. If the particle of dirt is under the upper lid, look for it by turning the lid up over a thin stick. The person should look down while you do this:



The particle is often found in the small groove near the edge of the lid. Remove it with the corner of a clean cloth.

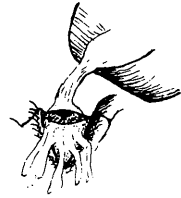If you cannot get the particle out easily, use an antibiotic eye ointment, cover the eye with a bandage, and go for medical help.

CHEMICAL BURNS OF THE EYE

Battery acid, lye, gasoline, or a pesticide that gets into the eye can be dangerous. Hold open the eye.

Immediately flood the eye with clean, cool water.

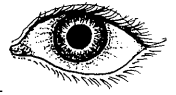Keep flooding for 30 minutes, or until it stops hurting. Do not let the water get into the other eye.



RED, PAINFUL EYES—DIFFERENT CAUSES

Many different problems cause red, painful eyes. Correct treatment often depends on finding the cause, so be sure to check carefully for signs of each possibility. This chart may help you find the cause:

foreign matter (bit of dirt, etc.) in the eye (p. 218)	usually affects one eye only ; redness and pain variable
burns or harmful liquids (p. 219)	one or both eyes; redness and pain variable
'pink eye' (conjunctivitis, p. 219) hay fever (allergic conjunctivitis, p. 165) trachoma (p. 220) measles (p. 311)	usually both eyes (may start or be worse in one) usually reddest at outer edge 'burning' pain, usually mild
acute glaucoma (p. 222) iritis (p. 221) scratch or ulcer on the cornea (p. 224)	usually one eye only ; reddest next to the cornea pain often great




'PINK EYE' (CONJUNCTIVITIS)

This infection causes redness, pus, and mild 'burning' in one or both eyes. Lids often stick together after sleep. It is especially common in children.

Treatment:

First clean pus from the eyes with a clean cloth moistened with boiled water. Then put in antibiotic eye ointment (p. 378). Pull down the lower lid and put a little bit of ointment **inside**, like this: Putting ointment outside the eye does no good.



CAUTION: Do not touch the tube against the eye.

Prevention:

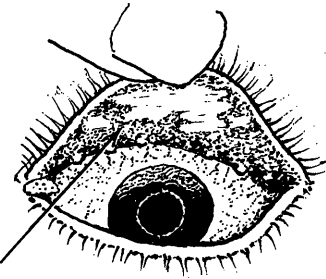
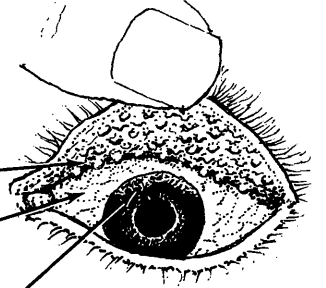
Most conjunctivitis is very contagious. The infection is easily spread from one person to another. Do not let a child with pink eye play or sleep with others, or use the same towel. Wash hands after touching eyes.

TRACHOMA

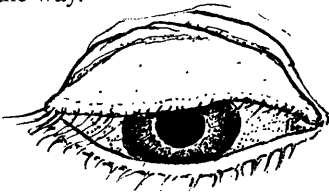
Trachoma is a chronic infection that slowly gets worse. It may last for months or many years. If not treated early, it sometimes causes blindness. It is spread by touch or by flies, and is most common where people live in poor, crowded conditions.

Signs:

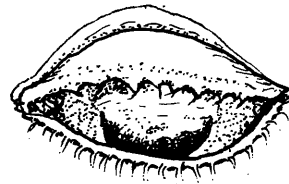
- Trachoma begins with red, watery eyes, like ordinary conjunctivitis.
- After a month or more, small, pinkish gray lumps, called follicles, form inside the upper eyelids. To see these, turn back the lid as shown on p. 218.
- The white of the eye is a little red.
- After a few months, if you look very carefully, or with a magnifying glass, you may see that the top edge of the cornea looks grayish, because it has many tiny new blood vessels in it (*pannus*).
- The combination of both follicles and pannus is almost certainly trachoma.
- After several years, the follicles begin to disappear, leaving whitish scars.



These scars make the eyelids thick and may keep them from opening or closing all the way.



Or the scarring may pull the eyelashes down into the eye, scratching the cornea and causing blindness.



Treatment of trachoma:

Put 1% tetracycline or erythromycin eye ointment (p. 378) inside the eye 3 times each day, or 3% tetracycline or erythromycin eye ointment 1 time each day. Do this for 30 days. For a complete cure, also take tetracycline (p. 356), erythromycin (p. 355) or a sulfonamide (p. 358) by mouth for 2 to 3 weeks.

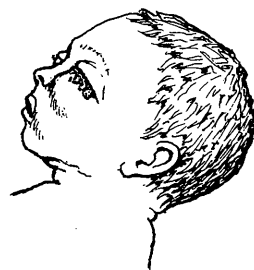Prevention:

Early and complete treatment of trachoma helps prevent its spread to others. All persons living with someone who has trachoma, especially children, should have their eyes examined often and if signs appear, they should be treated early. Washing the face every day can help prevent trachoma. Also, it is very important to follow the Guidelines of Cleanliness, explained in Chapter 12.

Cleanliness helps prevent trachoma.

INFECTED EYES IN NEWBORN BABIES (NEONATAL CONJUNCTIVITIS)

In the first 2 days of life, if a newborn baby's eyes get red, swell, and have a lot of pus in them, this is probably **gonorrhea** (p. 236). It must be treated **at once** to prevent the baby from going blind. If the eye infection begins between 1 and 3 weeks after birth, she may have **chlamydia**. The baby has picked up one or both of these diseases from the mother at birth.



Treatment for gonorrhea:

- ◆ Give one injection of 50 to 75 mg. of kanamycin (see p. 359). Or, penicillin sometimes works: inject 200,000 units of crystalline penicillin twice a day for 3 days. Or, try 1/2 teaspoon of co-trimoxazole syrup by mouth 2 times a day for a week (see p. 358). (If available, one injection of 125 mg. of ceftriaxone is the best treatment.)
- Also use tetracycline or erythromycin eye ointment: put a little in the baby's eyes every hour for the first day, and then 3 times a day for 2 weeks. (First clean out the pus as described on p. 219.)

Treatment for chlamydia: Treat with tetracycline or erythromycin ointment as described above. Also give erythromycin syrup by mouth, 30 mg. 4 times a day for 2 weeks. (This will treat pneumonia, which often affects babies with chlamydia.)

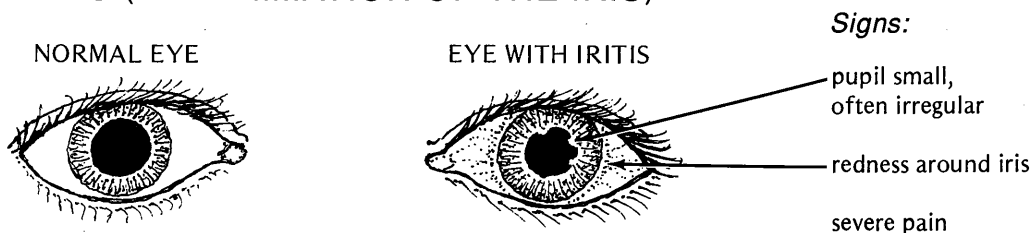
Prevention:

All babies' eyes should be protected against gonorrhea and chlamydia, especially the eyes of babies whose mothers may have these diseases or whose fathers have pain when passing urine. (Mothers may have gonorrhea or chlamydia without knowing it.)

Put a little 1 % tetracycline, erythromycin or chloramphenicol eye ointment in each eye at birth (see p. 379). Or, if you do not have eye ointment, put a drop of 1% silver nitrate solution **once only** in each eye at birth.

If a baby develops gonorrhea or chlamydia of the eyes, **both** parents should be treated for these infections (p. 236).

IRITIS (INFLAMMATION OF THE IRIS)



Iritis usually happens in one eye only. Pain may begin suddenly or gradually. The eye waters a lot. It hurts more in bright light. The eyeball hurts when you touch it. There is no pus as with conjunctivitis. Vision is usually blurred.

This is an emergency. Antibiotic ointments do not help. **Get medical help.**

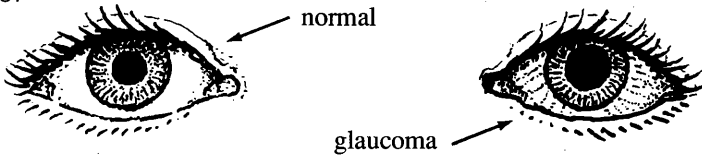
GLAUCOMA

This dangerous disease is the result of too much pressure in the eye. It usually begins after the age of 40 and is a common cause of blindness. **To prevent blindness, it is important to recognize the signs of glaucoma and get medical help fast.**

There are 2 forms of glaucoma.

ACUTE GLAUCOMA:

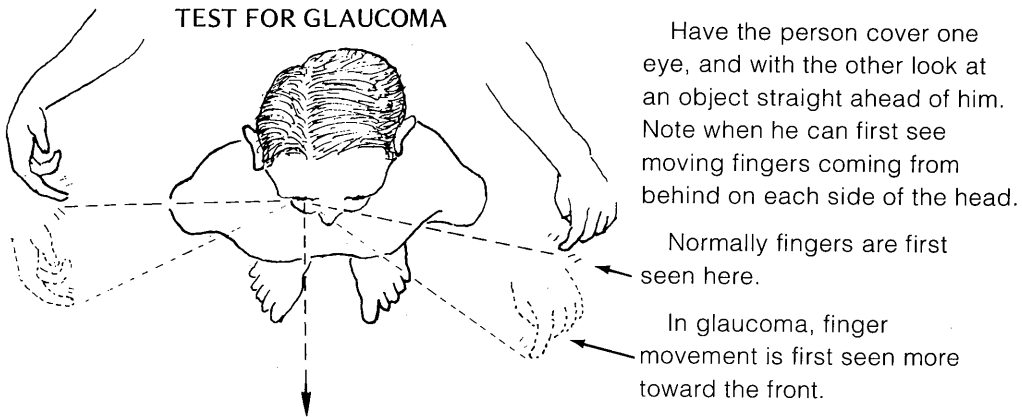
This starts suddenly with a headache or severe pain in the eye. The eye becomes red, the vision blurred. The eyeball feels hard to the touch, like a marble. There may be vomiting. The pupil of the bad eye is bigger than that of the good eye.



If not treated very soon, acute glaucoma will cause blindness within a few days. Surgery is often needed. **Get medical help fast.**

CHRONIC GLAUCOMA:

The pressure in the eye rises slowly. Usually there is no pain. Vision is lost slowly, starting from the side, and often the person does not notice the loss. Testing the side vision may help detect the disease.



If discovered early, treatment with special eyedrops (pilocarpine) may prevent blindness. Dosage should be determined by a doctor or health worker who can measure the eye pressure periodically. Drops must be used for the rest of one's life. When possible, eye surgery is usually the surest form of treatment.

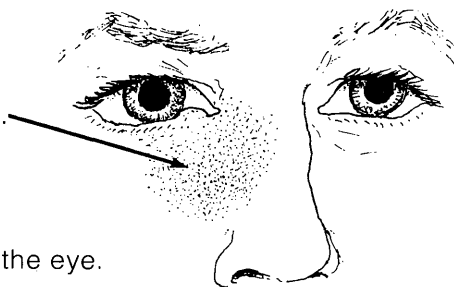Prevention:

Persons who are over 40 years old or have relatives with glaucoma should try to have their eye pressure checked once a year.

INFECTION OF THE TEAR SAC (DACRYOCYSTITIS)

Signs:

Redness, pain, and swelling beneath the eye, next to the nose. The eye waters a lot. A drop of pus may appear in the corner of the eye when the swelling is gently pressed.



Treatment:

- ◆ Apply hot compresses.
- ◆ Put antibiotic eye drops or ointment in the eye.
- ◆ Take penicillin (p. 351).

TROUBLE SEEING CLEARLY

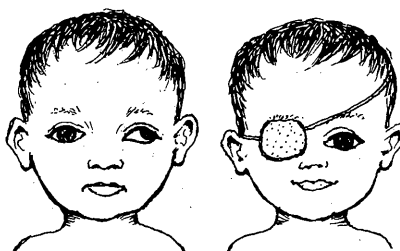
Children who have trouble seeing clearly or who get headaches or eye pain when they read may need glasses. Have their eyes examined.

In older persons, it is normal that, with passing years, it becomes more difficult to see close things clearly. Reading glasses often help. Pick glasses that let you see clearly about 40 cm. (15 inches) away from your eyes. If glasses do not help, see an eye doctor.



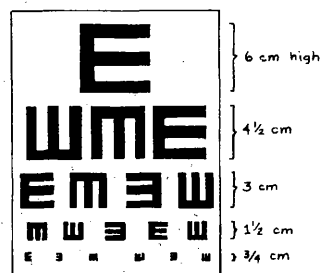
CROSS-EYES AND A WANDERING OR 'LAZY' EYE (STRABISMUS, 'SQUINT')

If the eye sometimes wanders like this, but at other times looks ahead normally, usually you need not worry. The eye will grow straighter in time. But if the eye is always turned the wrong way, and if the child is not treated at a very early age, she may never see well with that eye. See an eye doctor as soon as possible to find out if patching of the good eye, surgery, or special glasses might help.



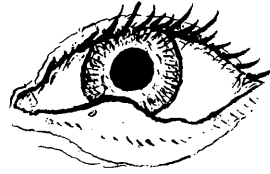
Surgery done at a later age can usually straighten the eye and improve the child's appearance, but it will not help the weak eye see better.

IMPORTANT: The eyesight of every child should be checked as early as possible (best around 4 years). You can use an 'E' chart (see *Helping Health Workers Learn*, p. 24-13). Test each eye separately to discover any problem that affects only one eye. If sight is poor in one or both eyes, see an eye doctor.



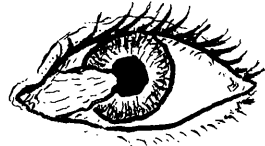
STY (HORDEOLUM)

A red, swollen lump on the eyelid, usually near its edge. To treat, apply warm, moist compresses with a little salt in the water. Use of an antibiotic eye ointment 3 times a day will help prevent more sties from occurring.



PTERYGIUM

A fleshy thickening on the eye surface that slowly grows out from the edge of the white part of the eye near the nose and onto the cornea; caused in part by sunlight, wind, and dust. Dark glasses may help calm irritation and slow the growth of a pterygium. It should be removed by surgery before it reaches the pupil. Unfortunately, after surgery a pterygium often grows back again.

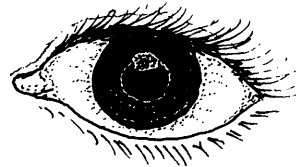


Folk treatments using powdered shells do more harm than good. To help calm itching and burning you can try using cold compresses. Or use eye drops of camomile (well boiled, then cooled, and without sugar).

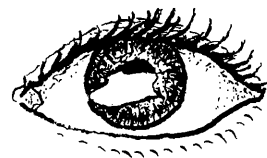
A SCRAPE, ULCER, OR SCAR ON THE CORNEA

When the very thin, delicate surface of the cornea has been scraped, or damaged by infection, a painful **corneal ulcer** may result. If you look hard in a good light, you may see a grayish or less shiny patch on the surface of the cornea.

If not well cared for, a corneal ulcer can cause blindness. Apply antibiotic eye ointment, 4 times a day for 7 days, give penicillin (p. 351), and cover the eye with a patch. If the eye is not better in 2 days, get medical help.




A **corneal scar** is a painless, white patch on the cornea. It may result from a healed corneal ulcer, burn, or other injury to the eye. If both eyes are blind but the person still sees light, surgery (corneal transplant) to one eye may return its sight. But this is expensive. If one eye is scarred, but sight is good in the other, avoid surgery. Take care to protect the good eye from injury.



BLEEDING IN THE WHITE OF THE EYE

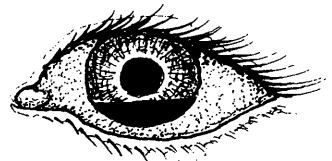
A painless, blood-red patch in the white part of the eye occasionally appears after lifting something heavy, coughing hard (as with whooping cough), or being hit on the eye. The condition results from the bursting of a small vessel. It is harmless, like a bruise, and will slowly disappear without treatment in about 2 weeks.



Small red patches are common on the eyes of newborn babies. No treatment is needed.

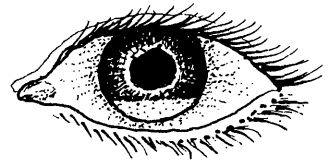
BLEEDING BEHIND THE CORNEA (HYPHEMA)

Blood behind the cornea is a danger sign. It usually results from an injury to the eye with a blunt object, like a fist. If there is pain and loss of sight, refer the person to an eye specialist immediately. If the pain is mild and there is not loss of sight, patch both eyes and keep the person at rest in bed for several days. If after a few days the pain becomes much worse, there is probably hardening of the eye (glaucoma, p. 222). Take the person to an eye doctor **at once**.



PUS BEHIND THE CORNEA (HYPOPYON)

Pus behind the cornea is a sign of severe *inflammation*. It is sometimes seen with corneal ulcers and is a sign that the eye is in danger. Give penicillin (p. 351) and get medical help at once. If the ulcer is treated correctly, the hypopyon will often clear up by itself.



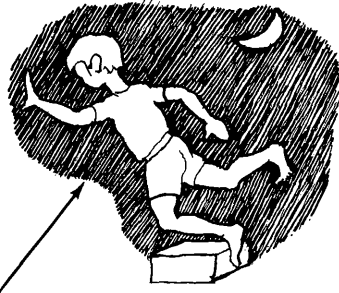
CATARACT

The lens of the eye, behind the pupil, becomes cloudy, making the pupil look gray or white when you shine a light into it. Cataract is common in older persons, but also occurs, rarely, in babies. If a blind person with cataracts can still tell light from dark and notice movement, surgery may let him see again. However, he will need strong glasses afterward, which take time to get used to. Medicines do not help cataracts. (Now sometimes during surgery an artificial lens is put inside the eye—so that strong eyeglasses are not needed.)



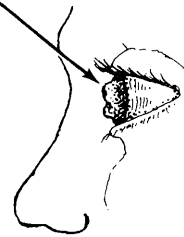
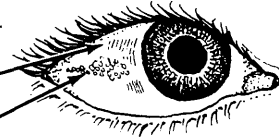
NIGHT BLINDNESS AND XEROPHTHALMIA (VITAMIN A DEFICIENCY)

This eye disease is most common in children between 1 and 5 years of age. It comes from not eating enough foods with vitamin A. If not recognized and treated early, it can make the child blind.



Signs:

- At first, the child may have **night blindness**. He cannot see as well in the dark as other people can.
- Later, he develops **dry eyes** (xerophthalmia). The white of the eyes loses its shine and begins to wrinkle.
- Patches of little gray bubbles (Bitot's spots) may form in the eyes.
- As the disease gets worse, the cornea also becomes dry and dull, and may develop little pits.
- Then the cornea may quickly grow soft, bulge, or even burst. Usually there is no pain. Blindness may result from infection, scarring, or other damage.
- Xerophthalmia often begins, or gets worse, when a child is sick with another illness like diarrhea, whooping cough, tuberculosis, or measles. **Examine the eyes of all sick and underweight children.** Open the child's eyes and look for signs of vitamin A deficiency.



Prevention and treatment:

Xerophthalmia can easily be prevented by eating foods that have vitamin A. Do the following:

- ◆ Breast feed the baby—up to 2 years, if possible.
- ◆ After the first 6 months, begin giving the child foods rich in vitamin A, such as dark green leafy vegetables, and yellow or orange fruits and vegetables such as papaya (paw paw), mango, and squash. Whole milk, eggs, and liver are also rich in vitamin A.
- ◆ If the child is not likely to get these foods, or if he is developing signs of night blindness or xerophthalmia, give him vitamin A, 200,000 units (60 mg. retinol, in capsule or liquid) once every 6 months (p. 392). Babies under 1 year of age should get 100,000 units.



- ◆ If the condition is already fairly severe, give the child 200,000 units of vitamin A the first day, 200,000 units the second day, and 200,000 units 14 days later. Babies under 1 year old should get half that amount (100,000 units).
- ◆ In communities where xerophthalmia is common, give 200,000 units of vitamin A once every 6 months to women who are breast feeding, and also to pregnant women during the second half of their pregnancy.

WARNING: Too much vitamin A is poisonous. Do not give more than the amounts advised here.

If the condition of the child's eye is severe, with a dull, pitted, or bulging cornea, get medical help. The child's eye should be bandaged, and he should receive vitamin A at once, preferably an injection of 100,000 units.

Dark green leafy vegetables, and yellow or orange fruits and vegetables, help prevent blindness in children.

SPOTS OR 'FLIES' BEFORE THE EYES (MOUCHES VOLANTES)


Sometimes older persons complain of small moving spots when they look at a bright surface (wall, sky). The spots move when the eyes move and look like tiny flies. These spots are usually harmless and need no treatment. But if they appear suddenly in large numbers and vision begins to fail from one side, this could be a medical emergency (detached retina). **Seek medical help at once.**

DOUBLE VISION

Seeing double can have many causes.


If double vision comes suddenly, is chronic, or gradually gets worse, it is probably a sign of a serious problem. Seek medical help.

If double vision occurs only from time to time, it may be a sign of weakness or exhaustion, perhaps from malnutrition. Read Chapter 11 on good nutrition and try to eat as well as possible. If sight does not improve, get medical help.



RIVER BLINDNESS (ONCHOCERCIASIS)

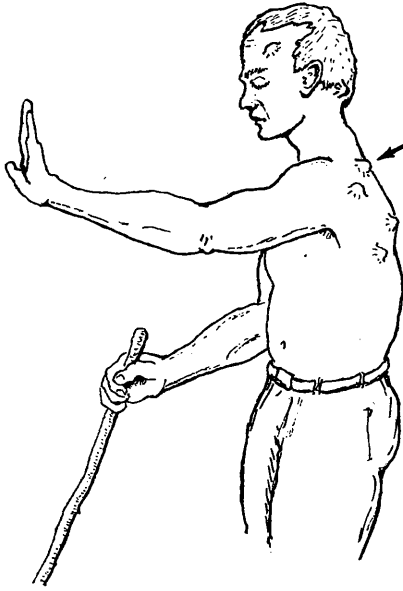
This disease is common in many parts of Africa and certain areas of southern Mexico, Central America, and northern South America. The infection is caused by tiny worms that are carried from person to person by small, hump-backed flies or gnats known as black flies (simuliids).



BLACK FLY

The worms are 'injected' into a person when an infected black fly bites him.

actual size → 

Signs of river blindness:

- Several months after a black fly bites and the worms enter the body, lumps begin to form under the skin. In the Americas the lumps are most common on the head and upper body; in Africa on the chest, the lower body, and thighs. Often there are no more than 3 to 6 lumps. They grow slowly to a size of 2 to 3 cm. across. They are usually painless.
 - There may be itching when the baby worms are spreading.
 - Pains in the back, shoulder or hip joints, or 'general pains all over'.
 - Enlargement of the lymph nodes in the groin.
 - Thickening of the skin on the back or belly, with big pores like the skin of an orange. To see this, look at the skin with light shining across it from one side.
- If the disease is not treated, the skin gradually becomes more wrinkled, like an old man's. White spots and patches may appear on the front of the lower legs. A dry rash may appear on the lower limbs and trunk.
 - Eye problems often lead to blindness. First there may be redness and tears, then signs of iritis (p. 221). The cornea becomes dull and pitted as in xerophthalmia (p. 226). Finally, sight is lost because of corneal scarring, cataract, glaucoma, or other problems.

Treatment of river blindness:

Early treatment can prevent blindness. In areas where river blindness is known to occur, seek medical testing and treatment when the first signs appear.

- ◆ Ivermectin (*Mectizan*) is the best medicine for river blindness, and it may be available at no cost through your local health department. Diethylcarbamazine and suramin are other medicines used to treat river blindness, but these can sometimes do more harm than good, especially when eye damage has already begun. They should only be given by experienced health workers. For dosage and precautions on all these medicines, see p. 378.
- ◆ Antihistamines help reduce itching (p. 386).
- ◆ Early surgical removal of the lumps lowers the number of worms.

Prevention:

- ◆ Black flies breed in fast-running water. Clearing brush and vegetation back from the banks of fast-running streams may help reduce the number.
- ◆ Avoid sleeping out-of-doors—especially in the daytime, which is when the flies usually bite.
- ◆ Cooperate with programs for the control of black flies.
- ◆ **Early treatment prevents blindness and reduces spread of the disease.**